



asx announcement

MESOBLAST DISC REPAIR RESULTS HIGHLIGHTED AT KEY ORTHOPAEDIC CONFERENCE

Melbourne, Australia; 15 September 2009: Mesoblast's successful preclinical disc repair trial was featured at the World Congress on Osteoarthritis held in Montréal, Canada, over the weekend.

More than 1,000 specialists in orthopaedics and rheumatology, as well as pain doctors and clinical scientists attended the prestigious congress conducted by the OsteoArthritis Research Society International (OARSI).

Internationally recognised cartilage expert, Professor Peter Ghosh, discussed how a single low-dose injection of Mesoblast's allogeneic or "off-the-shelf" adult stem cells into severely damaged intervertebral discs resulted in dramatic reversal of the degenerative process, regrowth of disc cartilage, and sustained normalisation of disc pathology, anatomy and function. Professor Ghosh's presentation is attached.

Mesoblast will continue to ensure that its achievements are highlighted and recognised at respected international conferences and meetings attended by key opinion leaders.

About Mesoblast

Mesoblast Limited (ASX:MSB) is committed to the development of novel treatments for orthopaedic conditions, including the rapid commercialisation of a unique adult stem cell technology aimed at the regeneration and repair of bone and cartilage. Our focus is to progress through clinical trials and international regulatory processes necessary to commercialise the technology in as short a timeframe as possible. Mesoblast has the worldwide exclusive rights for a series of patents and technologies developed over more than 10 years relating to the identification, extraction and culture of adult Mesenchymal Precursor Cells (MPCs). The Company has acquired 38.4% of Angioblast Systems Inc., an American company developing the platform MPC technology for the treatment of cardiac, vascular and eye diseases including repair and regeneration of blood vessels and heart muscle. Mesoblast and Angioblast are jointly funding and progressing the core technology. Mesoblast's strategy is to maximise shareholder value through both corporate partnerships and the rapid and successful completion of clinical milestones.

For further information, please contact:

Julie Meldrum
Corporate Communications Director
Mesoblast Limited
T: + 61 (03) 9639 6036
M: +61 (0) 419 228 128
E: julie.meldrum@mesoblast.com
W: www.mesoblast.com

**INJECTION OF ALLOGENEIC IMMUNOSELECTED STRO-3+
MESENCHYMAL PRECURSOR STEM CELLS INTO LUMBAR
INTERVERTEBRAL DISCS ATTENUATES DEGENERATION AND
PROMOTES THE RESTORATION OF THE DISC EXTRACELLULAR
MATRIX. AN EXPERIMENTAL STUDY IN AN OVINE MODEL OF DISC
DEGENERATION**

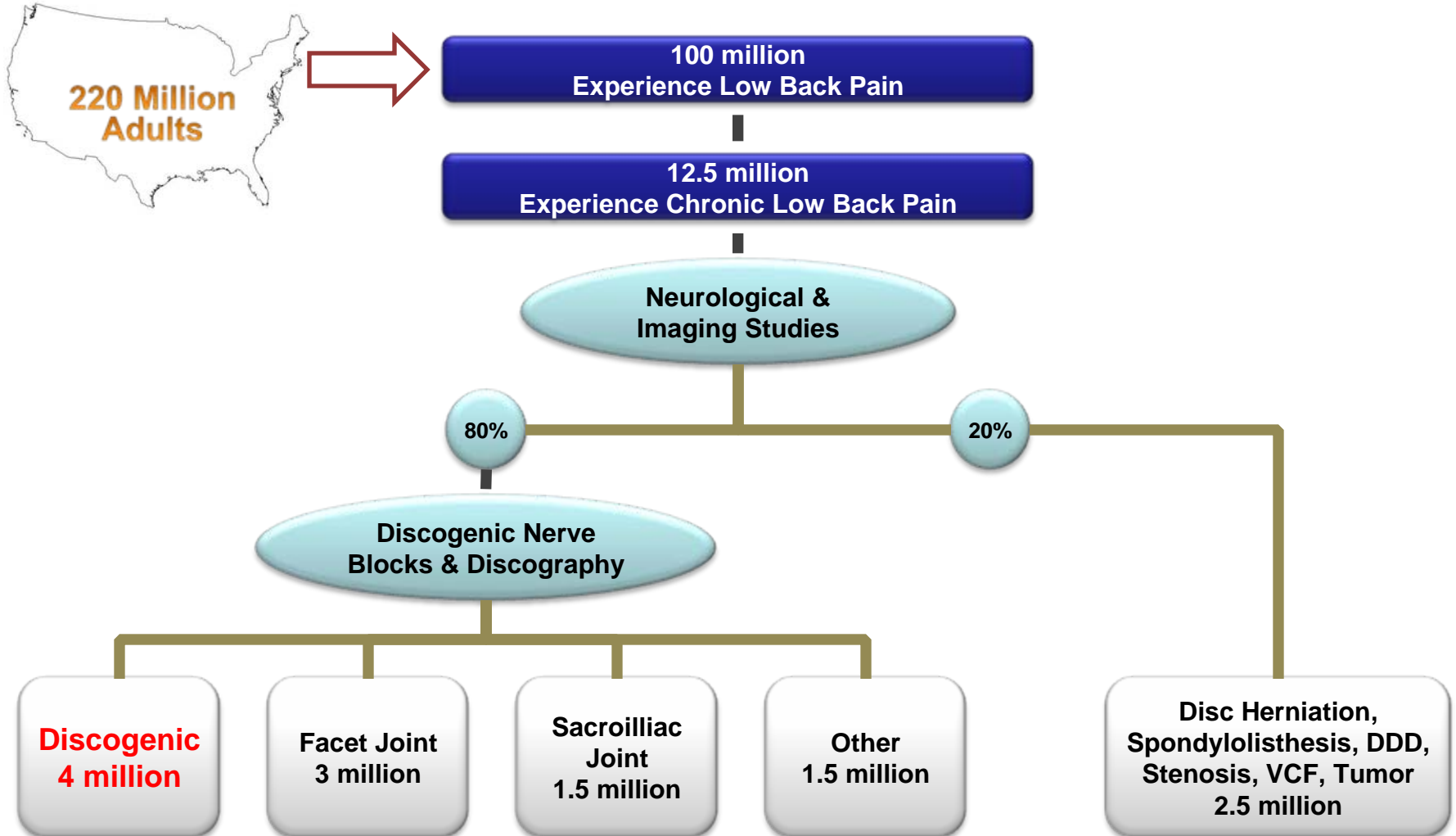
Peter Ghosh, Silviu Itescu, Robert Moore, Barrie Vernon-Roberts,
Tony Goldschlager, Andrew Zannettino, Stan Gronthos, Chris Little,
James Melrose, Cindy Shu

**Presented at the World Congress on Osteoarthritis held in Montreal Canada
September 10-14 2009.**

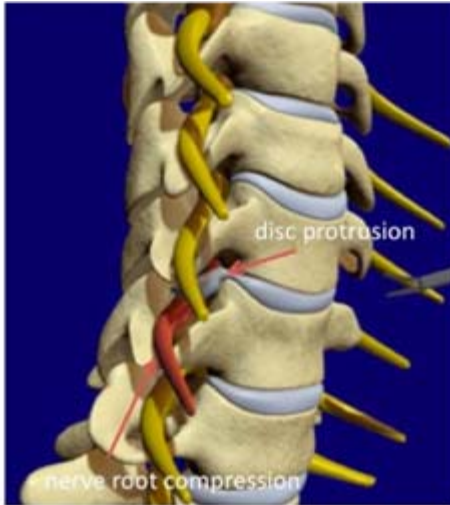

Prevalence of Anatomical Sources of Chronic Back Pain

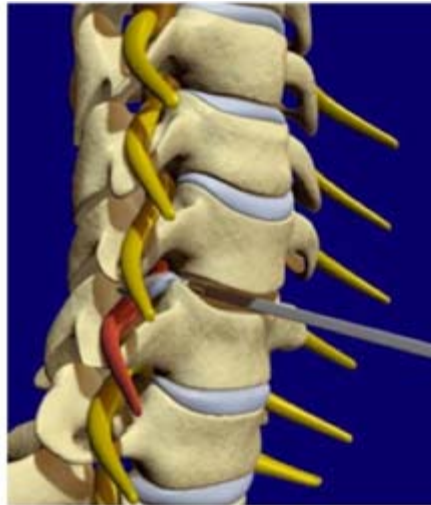(Data from: Deyo RA, et al. Back Pain Prevalence and Visit Rates. Spine. 2006; 23:2724-2727)



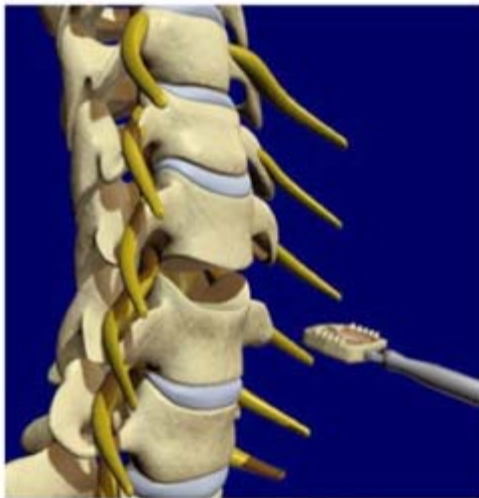Downside of spinal fusion



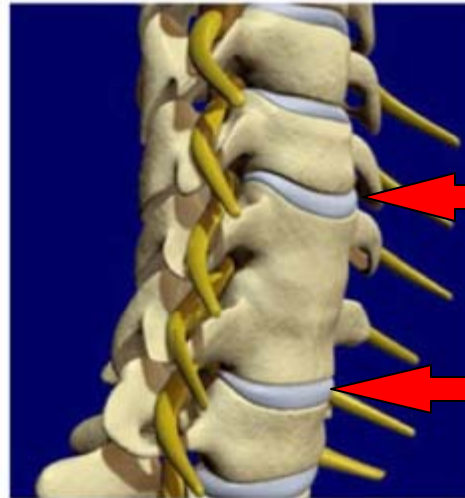
a. Antero-Lateral view



b. Total Discectomy



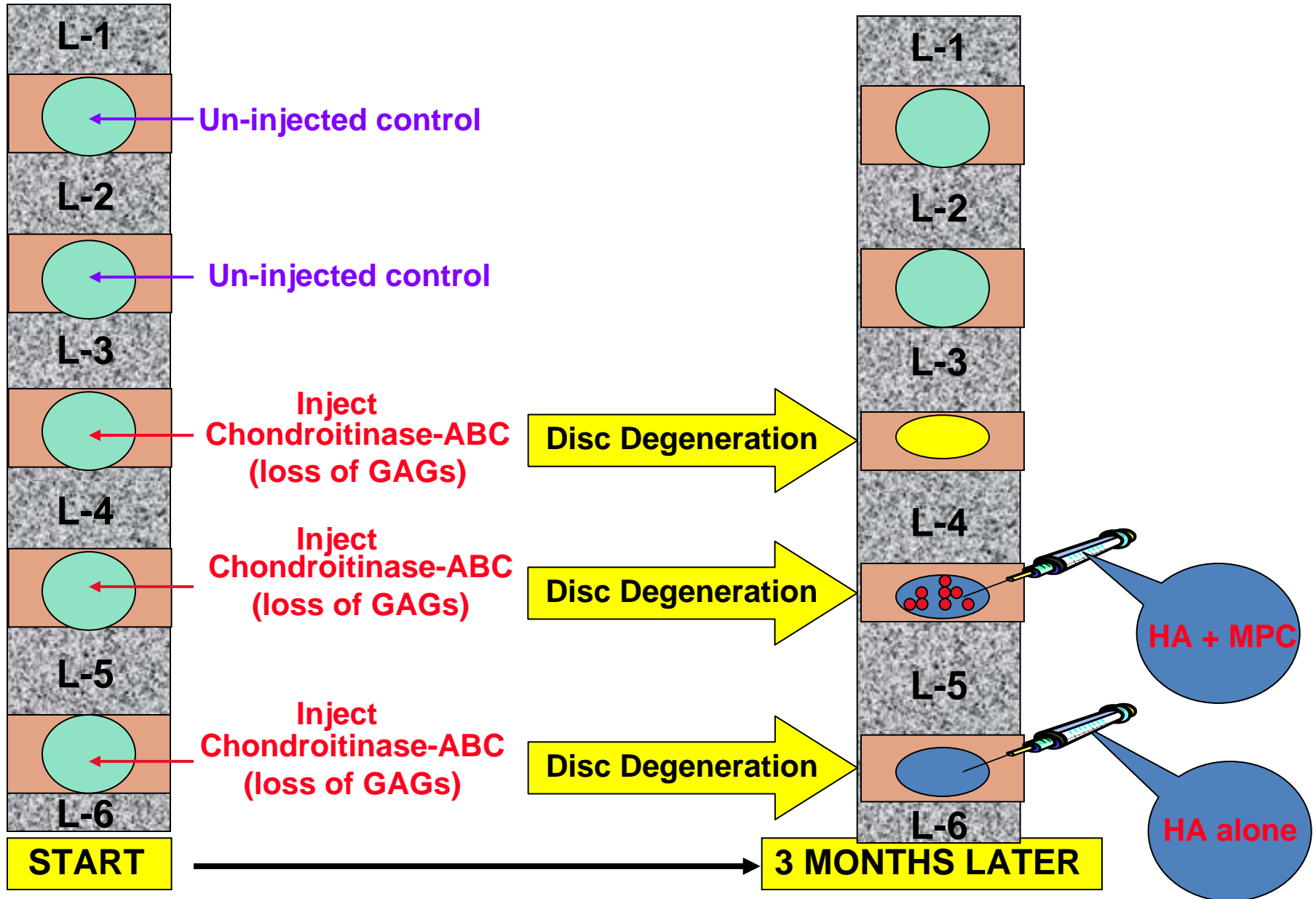
c. Interbody cage inserted following discectomy & nerve root decompression



d. Segment fused

Accelerated degeneration !

Sheep model to evaluate the re-constitution of degenerate discs by injections of MPC + hyaluronan (HA)

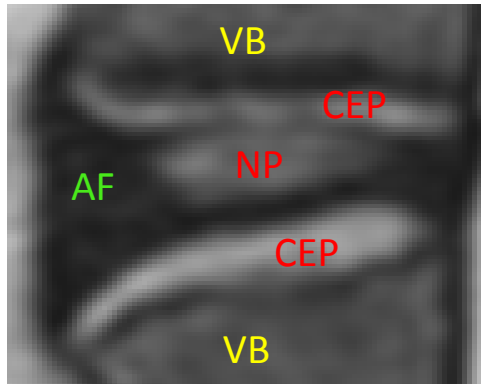


METHODS of ASSESSMENT

- **X-RAY** determination of disc height (DHI)
 - **MRI Scoring of Disc Degeneration**
- **Histopathology Scoring of disc sections**
- **Biochemical composition of Fixed disc tissues**

MRI determination of Disc Degeneration

T2 Weighted MRI, sagittal midline view of normal ovine lumbar intervertebral disc



Distinction between annulus fibrosus and nucleus pulposus component of Pfirrmann grading system, sagittal T2 Weighted MRI



I Clear



II Unclear



III Lost

Structure component of Pfirrmann grading system, sagittal T2 Weighted MRI



I Homogenous, bright white



II Inhomogenous with or without horizontal bands



III Inhomogenous, gray

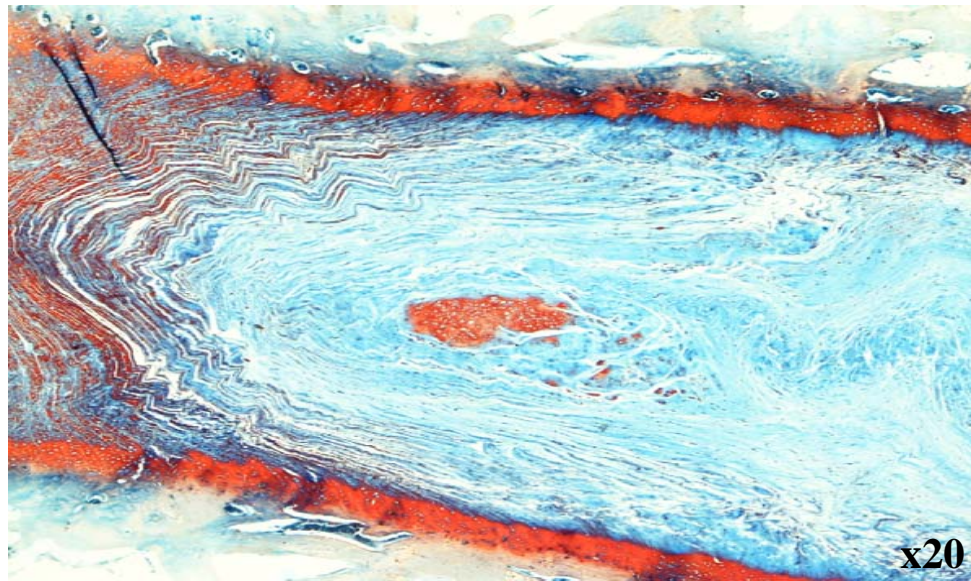


IV Inhomogenous, gray to black

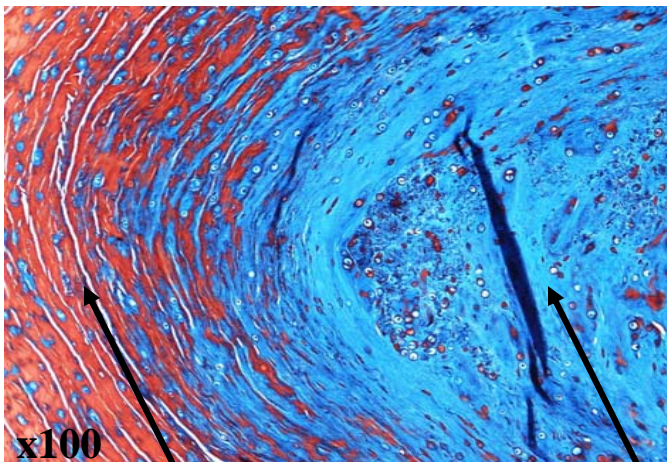


V Inhomogenous, black

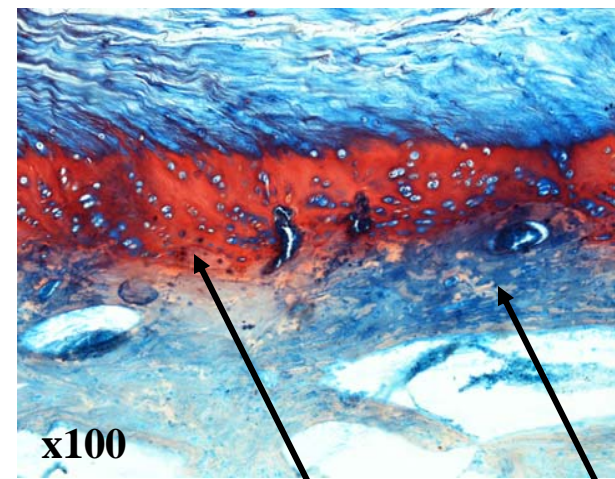
DISC HISTOPATHOLOGICAL GRADE 1 (Normal)



x20



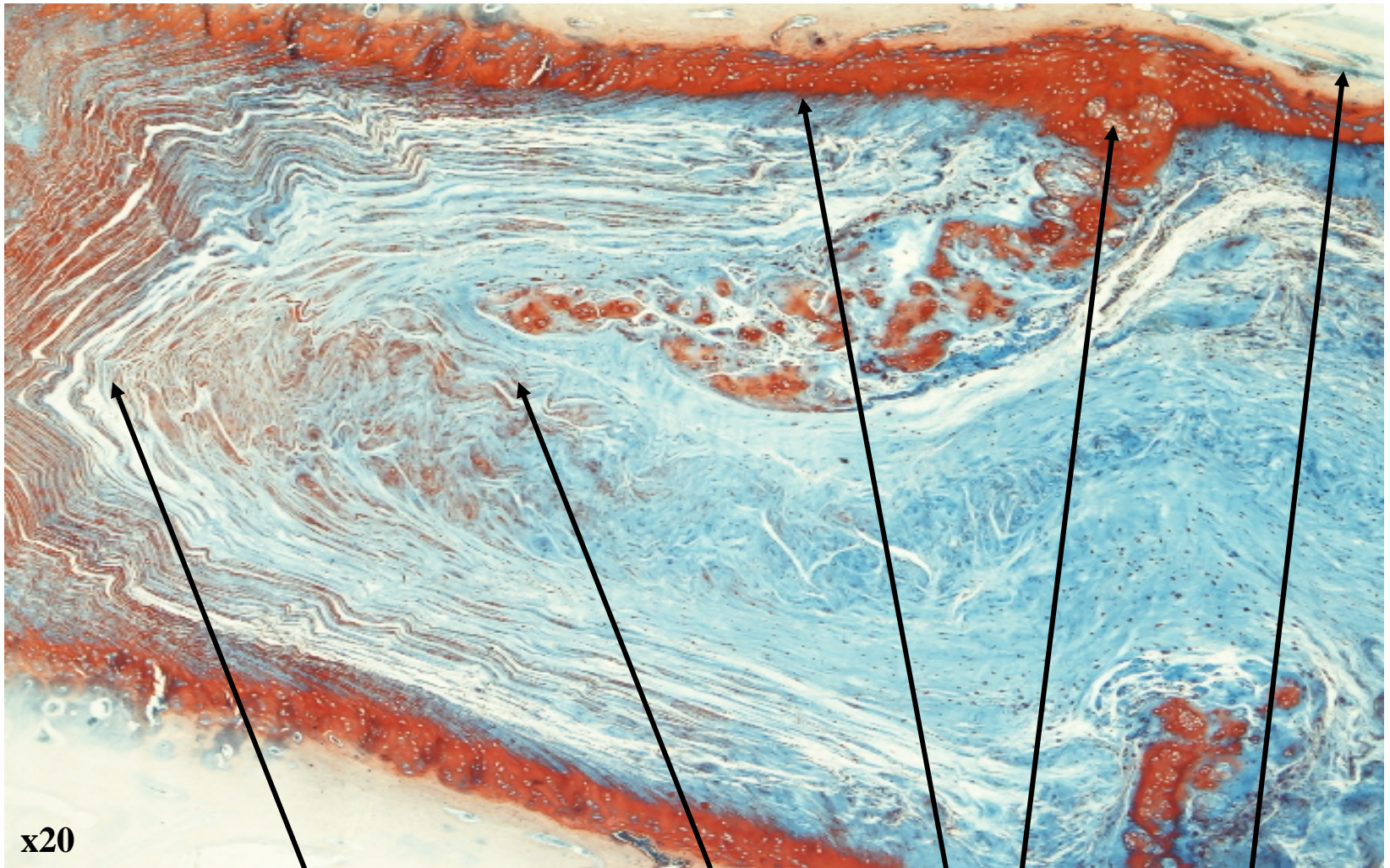
x100



x100

Grade	Annulus fibrosus	Nucleus pulposus	Cartilage end-plate	Margins/subchondral bone
1	Intact lamellae Narrow inter-lamellar matrix Intact annulus attachment Vessels only in outer 1/3	Homogeneity Absence of clefting	Uniform thickness Intact attachment to bone Uniform calcification <1/5 depth Uniform cell distribution	Even thickness of BEP Lamellar bone only Distinct junction with CEP Few vascular intrusions into CEP

DISC HISTOPATHOLOGICAL GRADE 2



x20

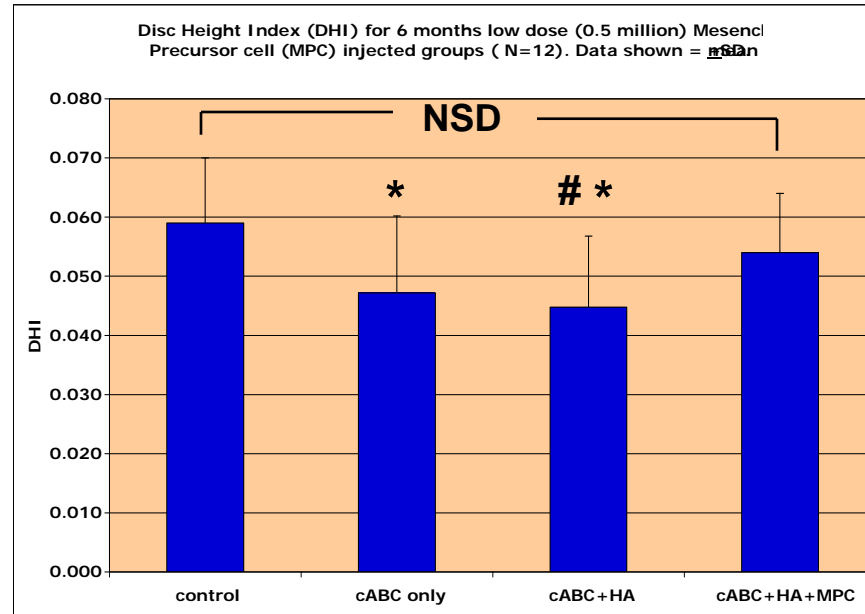
Grade	Annulus fibrosus	Nucleus pulposus	Cartilage end-plate	Margins/subchondral bone
2	Minor lamellar splitting and disorganisation. Minor widening matrix. Minor disorganisation of attachment Rim lesion without reparative reaction	Minor clefting Minor cell necrosis Minor posterior displacement of annulus Minor chondrone formation	Minor cartilage thinning Small transverse fissures Irregular thickening calcified zone Few invading vascular channels Small chondrones	Slightly uneven BEP Schmorl's nodes Minimal remodelling of BEP Small marginal osteophytes

RESULTS

- **Disc Height Index (DHI)**

Disc Height Index (DHI) 6 months after low dose Mesenchymal Precursor cells (0.5 million) were administered to discs degenerated by Chondroitinase-ABC treatment 3 months earlier

* $p < 0.05$ relative to control. # $p < 0.05$ relative to cABC+HA+MPC



By 6 months post treatment DHI for MPC injected discs higher than HA injected discs and equivalent to controls

RESULTS

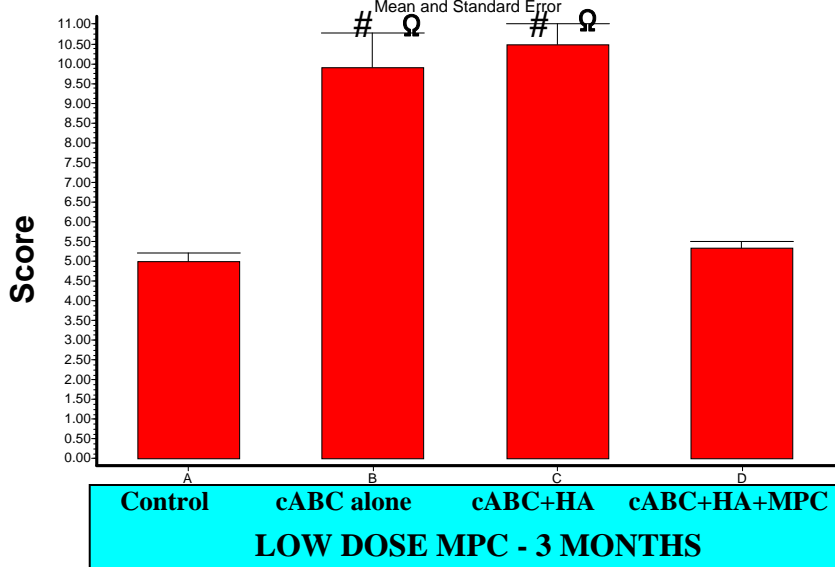
- MRI Degeneration SCORES

Aggregate MRI Disc Degeneration Scores

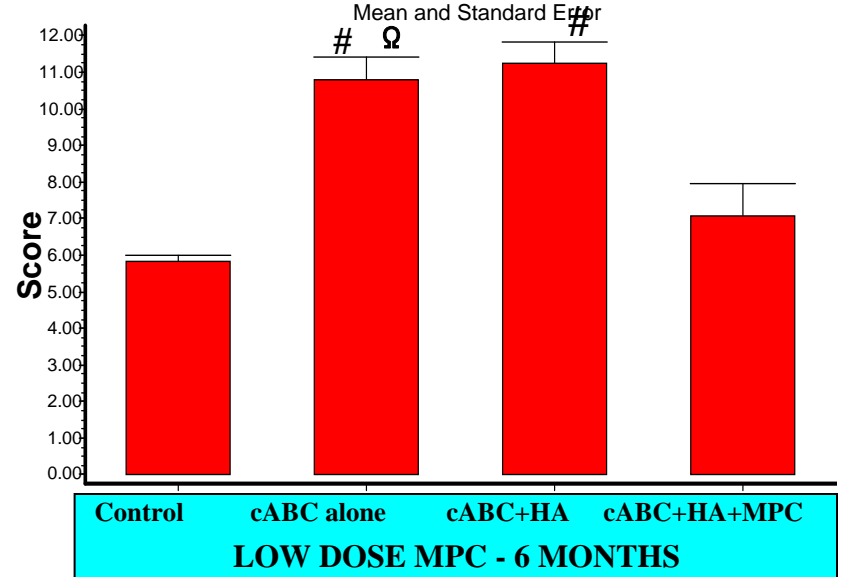
= significantly different from control $p < 0.05$ Ω = from MPC $p < 0.05$

#

Aggregate MRI Disc Degeneration Scores for LOW DOSE MPC at 3 months

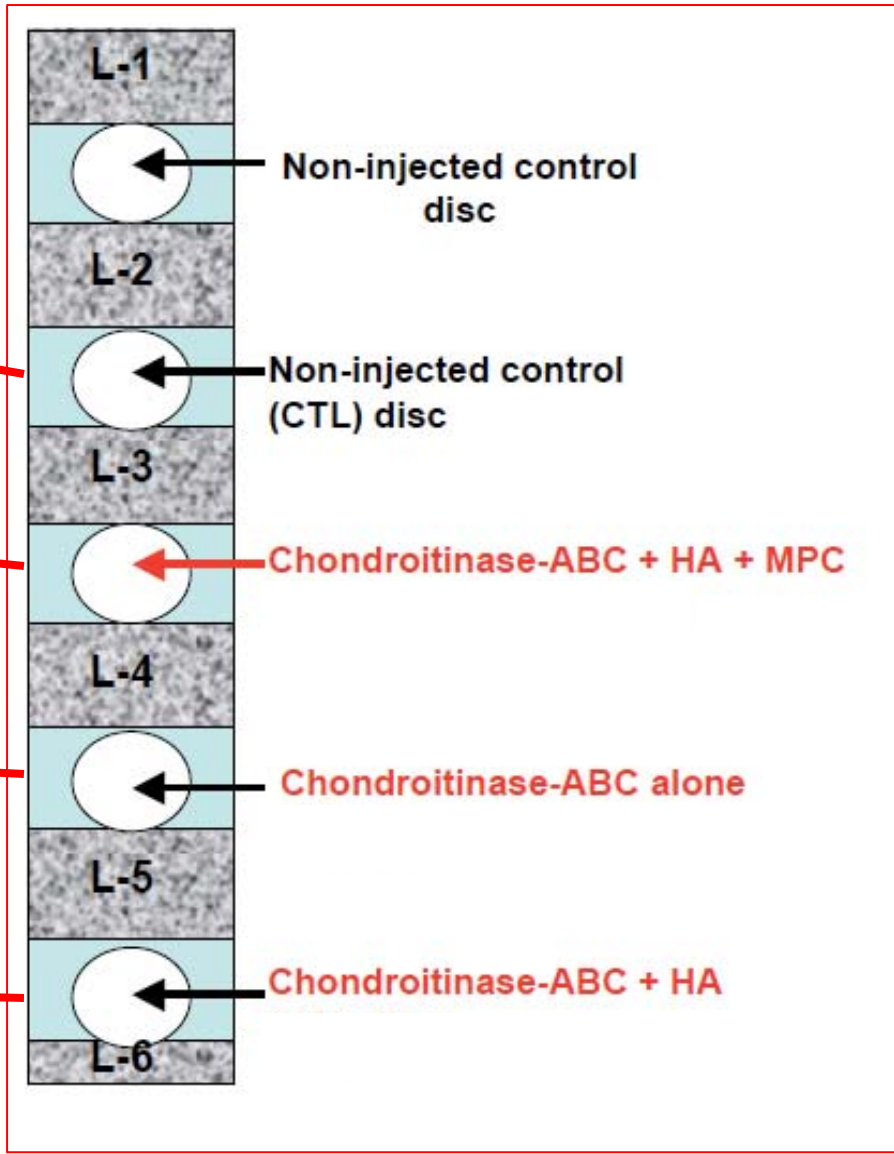
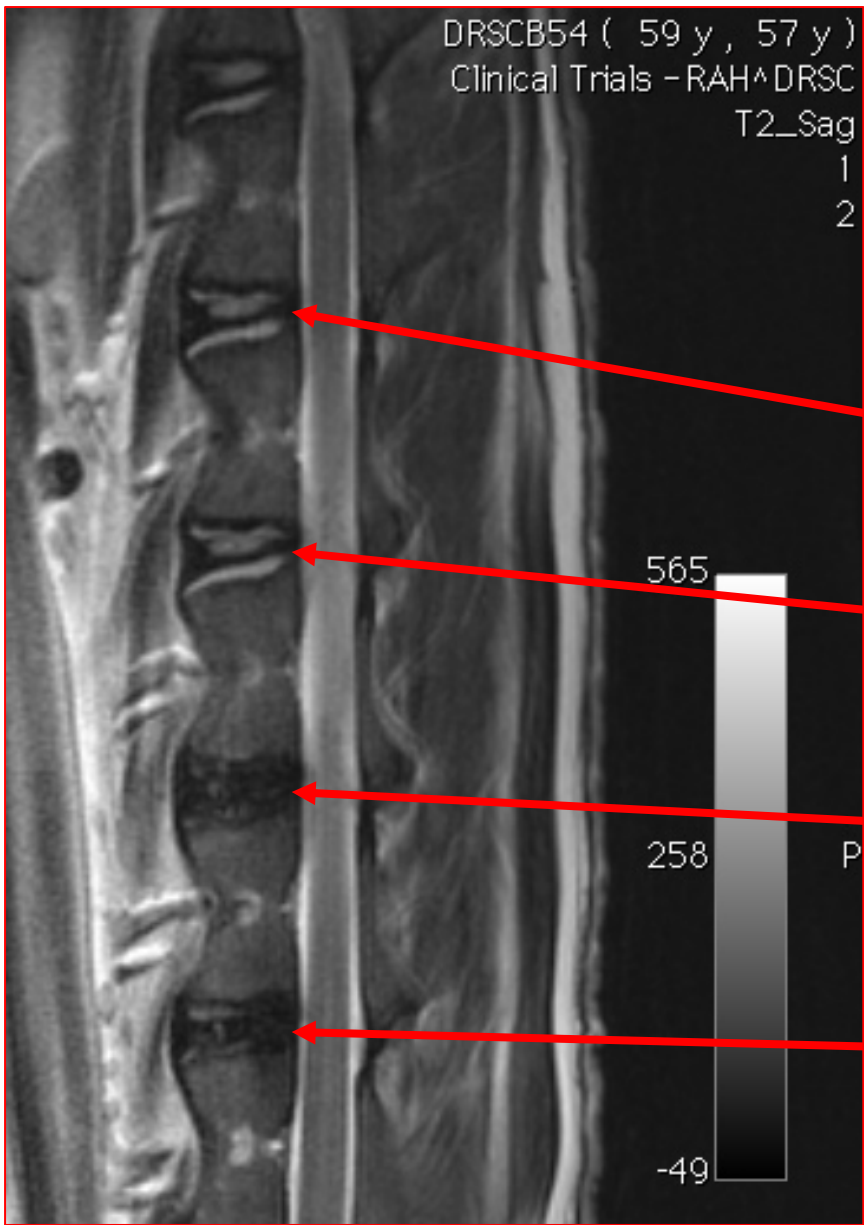


Aggregate MRI Disc Degeneration Scores for LOW DOSE MPC at 6 mo



At 3 and 6 months post treatment, aggregate MRI disc degeneration scores for MPC injected discs have normalised and are equivalent to controls

MRI of an ovine spine 6 months after injecting 0.5 million MPC showing similar H₂O signal (white) to normal control ovine disc. Note: L4L5 & L5L6 low H₂O signal



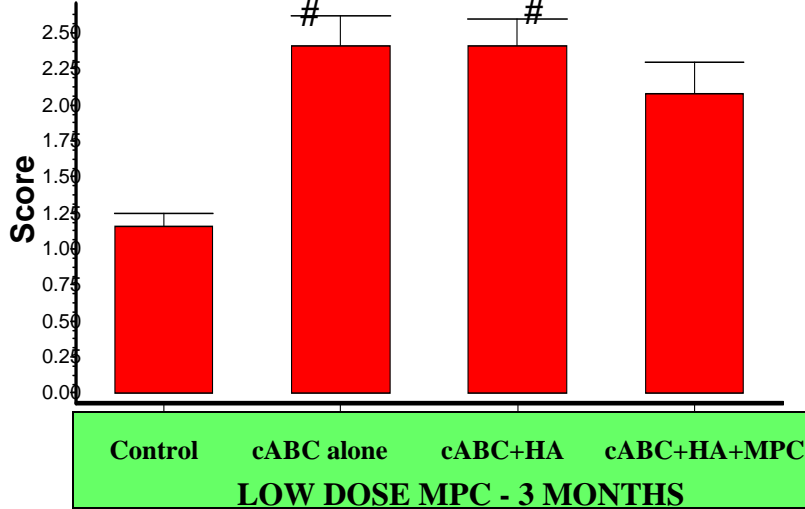
RESULTS

- HISTOPATHOLOGY SCORES

Aggregate Histopathology Disc Degeneration Scores

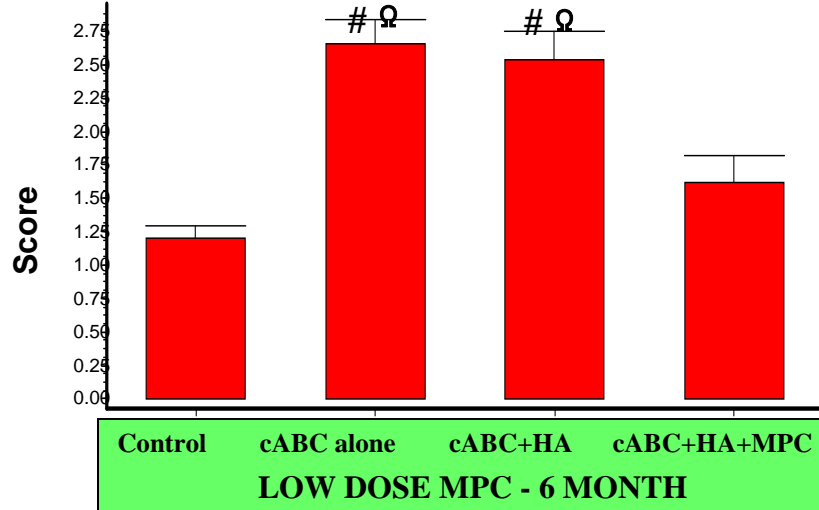
= significantly different from control $p < 0.001$; Ω = from MPC $p < 0.01$

Means of Aggregate Histopathology Disc Degeneration Scores at 3 Months
Mean and Standard Error



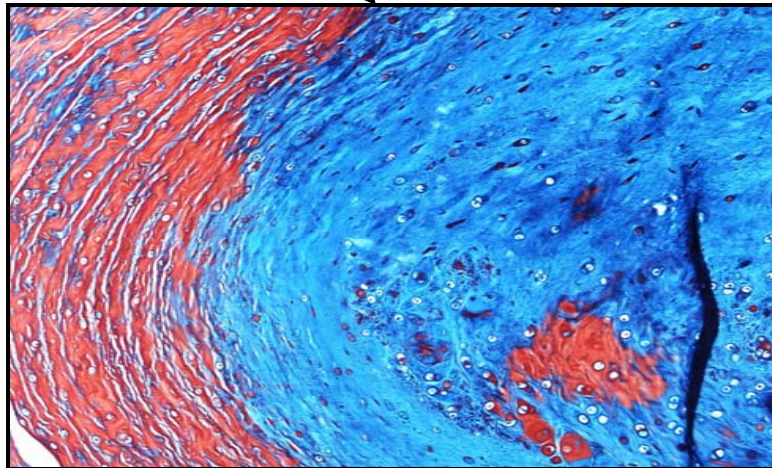
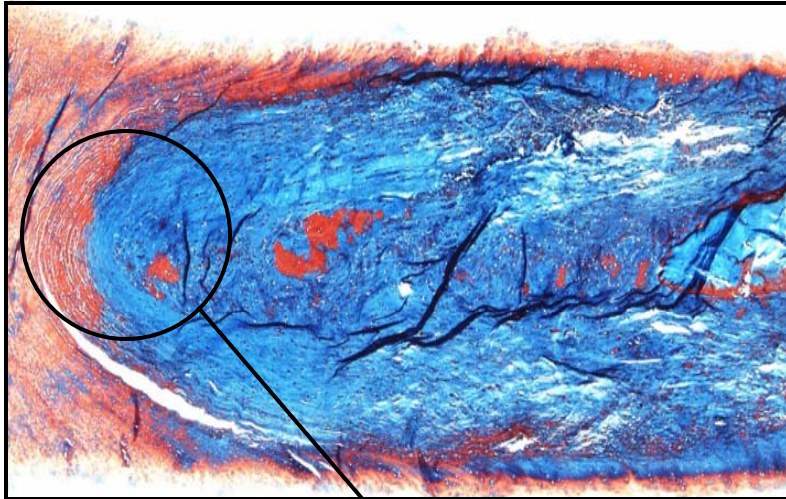
By 6 months post treatment, aggregate histopathological disc degeneration scores for MPC injected discs have normalised and are equivalent to controls

Means of Aggregate Histopathology Disc Degeneration Scores at 6 Months
Mean and Standard Error



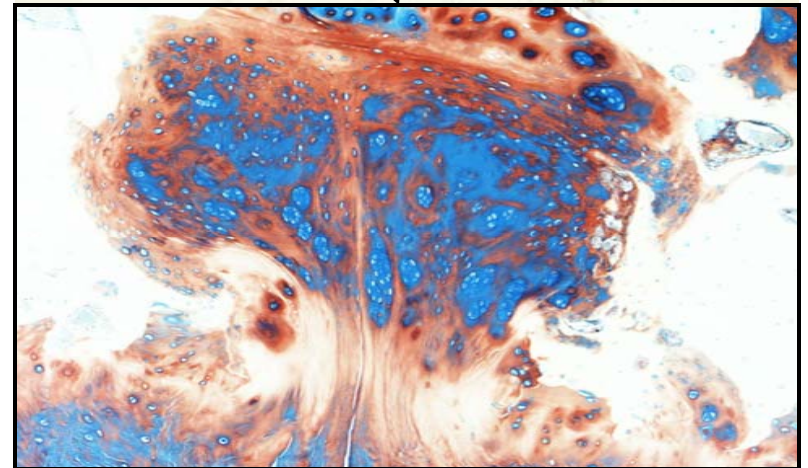
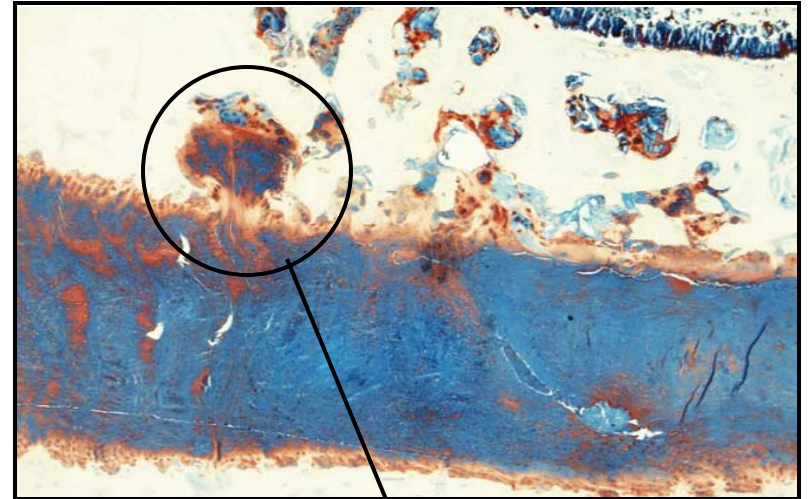
Photomicrographs of Alcian Blue/Neutral Red stained histological sections of lumbar discs from Sheep #61 (6 mths low MPC). Note the loss of AF structure CEP disruption in discs injected with Chondroitinase ABC+ Hyaluronan (cABC+HA)(Right panel) compared to discs injected with cABC+MPC (Left Panel).

cABC+MPC (overall score =1, AF score = 1) x20



cABC+MPC (overall score =1, AF score = 1) x100

cABC+HA (overall score = 4, CEP score = 4) x20




cABC+HA (overall score = 4, CEP score = 4) x100

DISC HISTOPATHOLOGY

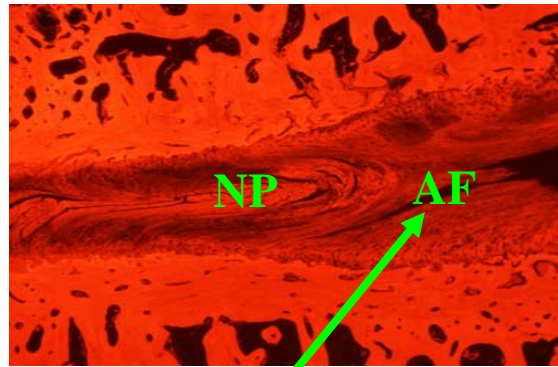
Photomicrographs of H&E stained histological sections of lumbar discs from Sheep #66 (6 mths low MPC) viewed under fluorescent light (λ 540-580 nM) to show the collagen fibre assembly. Note the loss of structural integrity of nucleus pulposus (NP) and annulus fibrosus (AF) of degenerate disc which received Chondroitinase ABC alone compared to the degenerate disc injected with 0.5 million MPC.

Normal Control Disc



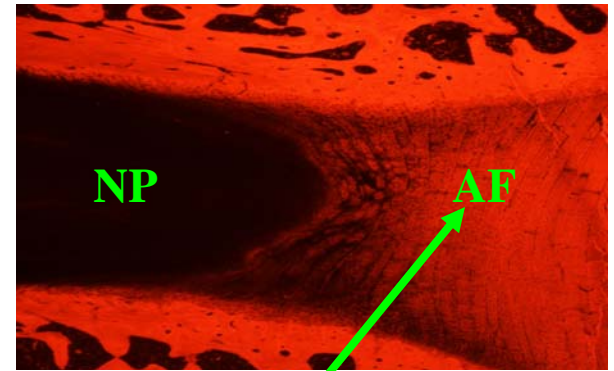
(AF histopath score = 1).
Magnificationx20

Degenerate Disc



(AF histopath score = 4).
Magnificationx20

Degenerate Disc + MPC



(AF histopath score = 1).
Magnificationx20

CONCLUSION

Injection of low-dose MPC (0.5×10^6) into degenerate discs normalises disc structure, reverses abnormal histopathology, and restores disc height